



International Journal of Advanced Community Medicine

E-ISSN: 2616-3594
P-ISSN: 2616-3586
www.comedjournal.com
IJACM 2021; 4(3): 01-03
Received: 01-05-2021
Accepted: 03-06-2021

Dr. Sheetal Sharma
Medical Officer,
MS Ophthalmology
Regional Hospital Una,
Himachal Pradesh, India

Dr. Sharat Kumar
Medical Officer,
MS Ophthalmology
Regional Hospital Kullu,
Himachal Pradesh, India

Dr. Eshani
MS Ophthalmology,
IGMC Shimla, Himachal
Pradesh, India

Dr. Sumit Singh Chauhan
MS Ophthalmology,
IGMC Shimla, Himachal
Pradesh, India

Corresponding Author:
Dr. Sheetal Sharma
Medical Officer,
MS Ophthalmology
Regional Hospital Una,
Himachal Pradesh, India

Assessment of acne vulgaris and its association with ocular dryness

Dr. Sheetal Sharma, Dr. Sharat Kumar, Dr. Eshani and Dr. Sumit Singh Chauhan

DOI: <https://doi.org/10.33545/comed.2021.v4.i3a.197>

Abstract

Background: Acne vulgaris is a chronic inflammatory disease of the pilosebaceous unit resulting from several interacting pathophysiologic factors. The present study was conducted to assess Acne vulgaris and its association with ocular dryness.

Materials & Methods: 86 patients with acne vulgaris underwent assessment of Schirmer's test, tear film breakup time (TBUT), tear film height, presence of conjunctival injection, punctate epithelial erosions (PEE), and meibomian gland dysfunction (MGD).

Results: Out of 86 patients, males were 56 and females were 30. Common complaints were watering & burning eyes in 42, foreign body sensation in 14, itching in 20, redness in 6 and on off vision blurring in 4 patients. The corneal findings were lustreless in 64, clear cornea in 12 and punctate lesions & lustreless cornea in 10 patients. The difference was significant ($P < 0.05$).

Conclusion: High prevalence of ocular findings in patients with acne vulgaris.

Keywords: acne vulgaris, burning eyes, ocular dryness

Introduction

Acne vulgaris is a chronic inflammatory disease of the pilosebaceous unit resulting from several interacting pathophysiologic factors. Among these, sebaceous gland hyperplasia with hyperseborrhea, abnormal keratinization with subsequent blockage of pilosebaceous ducts, bacterial colonisation of hair follicles by *Propionibacterium acnes* and inflammation are the most notable factors that contribute to acne development^[1].

Acne vulgaris is a common skin disease with prevalence reaching up to 80% during adolescence. It has a complex aetiology, involving abnormal keratinisation, hormonal function, bacterial growth, and immune hypersensitivity of pilosebaceous follicles of the head and upper trunk^[2]. The primary acne lesion is the "blackhead", an impaction and distension of the follicle with improperly desquamated keratinocytes and sebum. At puberty, when androgens stimulate the production of sebum, pre-existing comedones become filled with lipid and may enlarge to become visible^[3]. Inflammatory acne is the result of the host response to the follicular inhabitant *Propionibacterium acnes*. P acnes also activate complement and are generally inflammatory when brought into contact with the immune system. Non-ocular other disorders such as rosacea are often associated with MGD. This chronic inflammatory skin condition is found in areas with a dense distribution of sebaceous glands, and is more common during periods of increased sebum production^[4].

The most common adverse reactions observed during systemic acne treatment are mucocutaneous and ophthalmological. Ocular side effects associated with systemic acne treatment particularly with oral isotretinoin usage were investigated many times. These undesired ocular side effects include dry eye, blepharconjunctivitis, corneal opacities, abnormal meibomian gland secretion, conjunctival epitheliopathy, photophobia, and teratogenic ocular abnormalities^[5]. The present study was conducted to assess Acne vulgaris and its association with ocular dryness.

Materials & Methods

The present study comprised of 86 patients with acne vulgaris and ocular dryness of both genders. All were informed regarding the study and their written consent was obtained.

Data such as name, age, gender etc. was recorded. All underwent assessment of Schirmer's test, tear film breakup time (TBUT), tear film height, presence of conjunctival injection, punctate epithelial erosions (PEE), and meibomian gland dysfunction (MGD). Results thus obtained were subjected to statistical analysis. P value less than 0.05 was considered significant.

Results

Table I: Distribution of patients

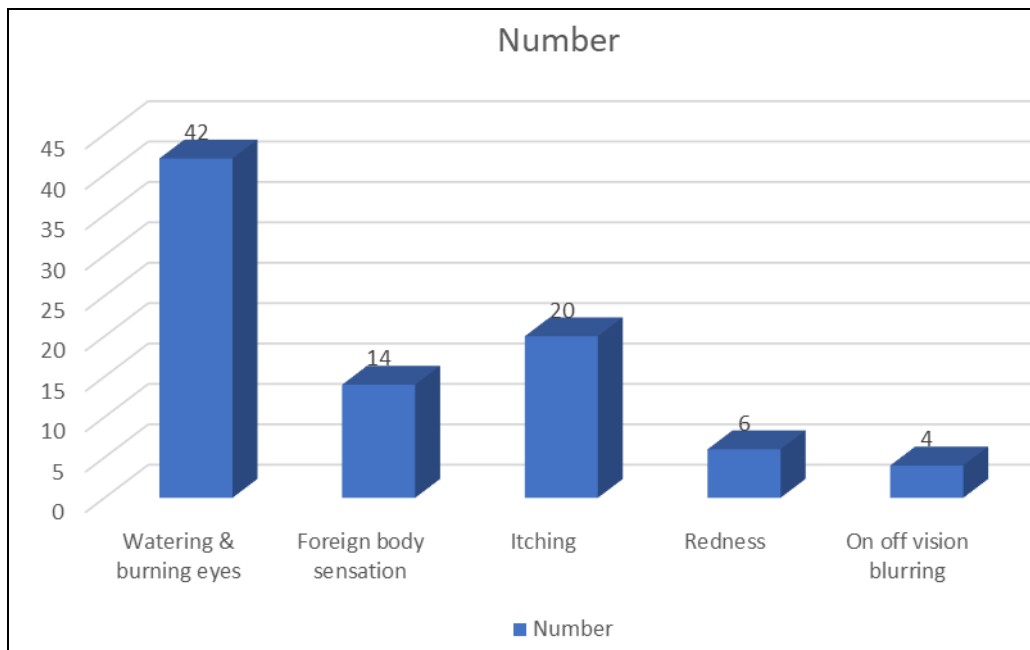
Total- 86		
Gender	Males	Females
Number	56	30

Table I shows that out of 86 patients, males were 56 and females were 30.

Table II: Complaints of patients

Complaints	Number	P value
Watering & burning eyes	42	0.02
Foreign body sensation	14	
Itching	20	
Redness	6	
On off vision blurring	4	

Table II, graph I shows that common complaints were watering & burning eyes in 42, foreign body sensation in 14, itching in 20, redness in 6 and on off vision blurring in 4 patients. The difference was significant ($P<0.05$).



Graph I: Complaints of patients

Table III: Assessment of corneal findings

Corneal findings	Number	P value
Lustureless	64	0.01
Clear cornea	12	
Punctate lesions & Lustureless cornea	10	

Table III shows that corneal findings were lustureless in 64, clear cornea in 12 and punctate lesions & lustureless cornea in 10 patients. The difference was significant ($P<0.05$).

Discussion

Acne vulgaris is a chronic inflammatory disease of the pilosebaceous unit resulting from several interacting pathophysiologic factors. Among these, sebaceous gland hyperplasia with hyperseborrhea, abnormal keratinization with subsequent blockage of pilosebaceous ducts, bacterial colonisation of hair follicles by Propionibacterium acnes and inflammation are the most notable factors that contribute to acne development. The available topical and systemic treatment options (medical treatment, lasers, light therapy) aim to interrupt the formation of the non-inflammatory lesions, inflammation, bacterial colonization and prevent complications including acne scars [6]. Medical treatment regimens with these targets are composed of

retinoids and antibiotics. Retinoids are important tools in the management of acne because they act against all major etiologic factors implicated in acne including abnormal keratinisation, the microcomedones and are also anti-inflammatory. Besides this, antibiotics are known to be the most effective therapy for inflammatory type of acne but due to potential for bacterial resistance, side effects and to increase efficacy usually combined therapy with retinoids is recommended.⁷ The present study was conducted to assess Acne vulgaris and its association with ocular dryness.

In present study, out of 86 patients, males were 56 and females were 30. Bayhan *et al.* [8] assessed the ocular side effects during topical retinoid-antibiotic combination treatment in patients with facial acne vulgaris in forty-three patients applying topical isotretinoin + erythromycin combination once daily for the treatment of acne vulgaris were enrolled. The mean age of the patients was 23.16 (18–30) years. Mean tear osmolarity increased significantly from 282.09 mOsm/L at baseline to 300.39 mOsm/L after the treatment ($p<0.001$). BUT decreased from an average of 11.93 seconds at baseline to 6.65 seconds at the end of the first month ($p<0.001$). The OSDI score worsened significantly (5.41 vs 21.53, $p<0.001$) and punctate epitheliopathy was seen in 51% of eyes after the treatment.

The average Schirmer values were 13.09 and 12.41 mm/5 min before and at the end of the first month of the treatment, respectively ($p = 0.117$).

We found that common complaints were watering & burning eyes in 42, foreign body sensation in 14, itching in 20, redness in 6 and on off vision blurring in 4 patients. Das *et al.* ^[9] evaluated correlation between acne vulgaris and evaporative type of ocular dryness. All patients between 13 -30 years of age with acne vulgaris both inflammatory and non- inflammatory were screened randomly for dry eye using Schirmer's test, tear film breakup time (TBUT), tear film height, presence of conjunctival injection, punctate epithelial erosions (PEE) on flourescein stain. Meibomian gland dysfunction (MGD) was used to diagnose dry eye. Out of 200 patients male were [n=106] predominated and mostly in the age group of 21-25 years. After 3 months of treatment there was marked improvement in tear film break up time [TBUT] and Schirmer's test. Only 74 cases (37%) had punctate epithelial lesions and 36% cases had associated meibomian gland dysfunction.

We found that corneal findings were lustreless in 64, clear cornea in 12 and punctate lesions & lustreless cornea in 10 patients. Symptoms of Dry eye syndrome (DES), include irritation, redness, discharge, easily fatigued eyes and often blurring of vision. Dry eye occurs when either the eye does not produce enough tears or when the tears evaporate too quickly ^[10]. This can result from meibomian gland dysfunction, allergies, pregnancy, Sjogren's syndrome, vitamin A deficiency, LASIK surgery, and certain medications such as antihistamines, some blood pressure medication, hormone replacement therapy, and antidepressants. Chronic conjunctivitis such as from tobacco smoke exposure or infection may also lead to the condition. Diagnosis is mostly based on the symptoms though a number of other tests may be used. Blepharitis and Meibomian gland dysfunction are one of the most common causes of dry eyes ^[11].

Meibomian glands are modified sebaceous gland that keeps the ocular surface clean, healthy and well-lubricated. It follows that hormonal effects on gland function are likely to be significant. Sebaceous glands are relatively inactive until the teenage years, at which point they increase in size and secrete larger quantities of sebum. Both the increase in gland activity accompanying puberty and the decrease observed later in life are attributed to changes in androgen production. Inflammation of the meibomian glands (also known as meibomitis, meibomian gland dysfunction, or posterior blepharitis) causes the glands to be obstructed by thick waxy secretions leading to dry eyes ^[12].

Conclusion

Authors found that high prevalence of ocular findings in patients with acne vulgaris.

References

1. Michael AL, Christophe B, Jules B, Murat D, Gary NF, Schigeru K, *et al.* The definition and classification of dry eye disease: Report of the definition and classification subcommittee of the international dry eye workshop (2007). *Ocul Surf* 2007;5:75-92.
2. McCarty CA, Bansal AK, Livingston PM, Stanislavsky YL, Taylor HR. The epidemiology of dry eye in Melbourne, Australia. *Ophthalmology* 1998;105:1114-9.
3. Smith RE. The tear film complex: Pathogenesis and emerging therapies for dry eyes. *Cornea* 2005;24:1-7.
4. Kligman AM. An overview of acne. *J Invest Derm.* 1974; 62:268-287.
5. Goulden V, Stables GI, Cunliffe WJ. Prevalence of facial acne in adults. *J Am Acad Dermatol* 1999;41:577-80.
6. Leyden JJ. The evolving role of Propionibacterium acnes in acne. *Semin Cutan Med Surg* 2001;20:139-143.
7. Leyden JJ, McGinley KJ, Cavalieri S, Webster GF, Mills OH, Kligman AM. Propionibacterium acnes resistance to antibiotics in acne patients. *J Am Acad Derm* 1983;8:41-45.
8. Bayhan SA, Bayhan HA, Çölgeçen E, Gürdal C. Effects of topical acne treatment on the ocular surface in patients with acne vulgaris. *Contact Lens and Anterior Eye* 2016;39(6):431-4.
9. Das S, Verma S, Pradeep B. Acne Vulgaris and its Association with Ocular Dryness-A Randomised Hospital Based Study. *The Official Scientific Journal of Delhi Ophthalmological Society* 2020;30(3):32-6.
10. Knop E, Knop N, Brewitt H *et al.* Meibomian glands: part III. Dysfunction- argument for a discrete disease entity and as an important cause of dry eye. *Ophthalmologie* 2009;106(11):966-979.
11. Sullivan DA, Sullivan BD, Ullman MD, *et al.* Androgen influence on the meibomian gland. *Investigative Ophthalmology & Visual Science* 2000;41:3732-3742.
12. Vieira AC, Mannis MJ. "Ocular rosacea: common and commonly missed". *J Am Acad Dermatol* 2013;6:69.